Journal of the Neurological Sciences 329 (2013) 45–50

Contents lists available at SciVerse ScienceDirect

Journal of the Neurological Sciences

journal homepage: www.elsevier.com/locate/jns

Neuronal nuclear antigen (NeuN): A useful marker of neuronal immaturity in sudden unexplained perinatal death

Anna M. Lavezzi *, Melissa F. Corna, Luigi Matturri

"Lino Rossi" Research Center for the study and prevention of unexpected perinatal death and SIDS Department of Surgical, Reconstructive and Diagnostic Sciences, University of Milan, Italy

ARTICLE INFO

Article history:
Received 9 February 2013
Accepted 14 March 2013
Available online 7 April 2013

Keywords:
NeuN
SIDS
SIUDS
Neuropathology
Environmental risk factors
Maternal smoking

ABSTRACT

Introduction: In the developing brain neuronal differentiation is associated with permanent exit from the mitotic cycle. Neuronal nuclear antigen (NeuN) is a nuclear protein widely expressed in the mature postmitotic neurons.

Methods: We applied NeuN immunocytochemistry in 65 cases of perinatal death (16 victims of sudden intrauterine unexplained death syndrome/SIUDS, 19 of sudden infant death syndrome/SIDS and 30 controls) to test the physiological status of the brain neurons. In addition we applied both TUNEL and Caspase 3 immunohistochemical methods in order to highlight a possible relation between decreased NeuN expression and apoptotic outcome. We also attempted to see whether or not NeuN pathological changes can be related to cigarette smoke absorption in pregnancy.

Results: NeuN staining was considerably reduced or lost in SIUDS/SIDS compared to controls. However neurons with decreased NeuN-labeling showed no sign of apoptosis. A significant association was found between NeuN depletion and maternal smoking.

Conclusion: Altered NeuN expression can be a marker of immature and/or suffering neurons. The exclusive presence of this pattern of expression in SIUDS/SIDS victims, leads us to recommend the NeuN immunohistochemistry as a routine method in neuropathological protocols to convalidate a diagnosis of sudden perinatal death.

1. Introduction

The neuronal nuclear antigen (NeuN) is a specific protein expressed in post-mitotic neurons. The corresponding antibody, developed by Mullen in 1992 [1], primarily stains the neuronal nucleus, but the cytoplasm and dendrites are also immunoreactive, though to a lesser extent. Noteworthy it does not stain the immature nerve cells until they exit from the cell cycle and achieve a stage of development that at least approaches mature function. This is coincident with the migration of the neuroblasts from their birthplace in the embryonic neural tube to their final position, outgrowth of axons and generation of synapses [2–5].

With the inexplicable exception of several neuronal cell types, such as the Purkinje cells and the dentate nucleus neurons in the cerebellum, the neurons of the inferior olivary nucleus in the medulla oblongata and the glial cells, that generally are not recognized by the NeuN antibody, the vast majority of neurons is strongly NeuN positive already in fetal life [1,2].

In addition to representing a marker of maturing neurons, the NeuN immunohistochemistry can be applied in neuropathologic studies to highlight their physiological status. Precisely, while intense NeuN expression is shown by healthy neurons, a decreased NeuN positivity in postembryonic life can be indicative of degeneration of differentiated neurons. In particular, immunoreactivity is significantly weakened after a severe injury, such as cerebral hypoxia/ischemia [6–8]. Infants who have suffered fetal distress or perinatal asphyxia may show less brain NeuN immunostaining than infants who have not experienced such insults [2].

Stressors, such as hypoxia, hypercarbia and asphyxia are known as pathogenetic factors in SIDS [9–12], resulting in functional and/or morphological developmental alterations of brain neurons. Nevertheless, among the countless existing works in the literature on this field, our previous contributions included, there are no reports taking into consideration the NeuN expression as index of neuronal distress in SIDS.

Insofar, we aimed to evaluate the immunoexpression of NeuN in a group of victims already object of our prior studies but not formerly investigated in this regard. We reconsidered a total of 65 subjects aged from 17 gestational weeks to 10 postnatal months, who had died of known or unknown causes. Our aims were firstly to obtain basic information about the manifestation of NeuN in the study groups and to evaluate a possible wrong expression in sudden perinatal and infant death, in addition to specific morpho-functional alterations of the autonomic

* Corresponding author at: "Lino Rossi" Research Center for the study and prevention of unexpected perinatal death and SIDS Department of Biomedical, Surgical and Dental Sciences, University of Milan, Via della Commenda 19, 20122 Milano, Italy. Tel.: +39 02 50320821; fax: +39 02 50320823.

E-mail address: anna.lavezzi@unimi.it (A.M. Lavezzi).

0022-510X/$ – see front matter © 2013 Elsevier B.V. All rights reserved.
http://dx.doi.org/10.1016/j.jns.2013.03.012

nervous system we had already reported [13–19]. Then, in order to evaluate if the NeuN depletion can be indicative of neuronal degeneration, we applied the TUNEL method as hallmark of apoptosis [20,21] and Caspase3 immunohistochemistry as a signal of dying cells [22].

Finally, we considered a possible correlation between NeuN pathological changes and hypoxic injuries related to cigarette smoke absorption in pregnancy.

2. Methods

A total of 65 brains were considered for this study, from 29 fresh ante-partum stillbirths (17–40 gestational weeks—gw, mean age: 37 gw), and 36 infants aged between 1 and 10 months (mean age: 3.5 months).

For each case, a complete clinical history, with particular reference to the maternal lifestyle, and including the death scene examination for infant victims, was collected. None of the mothers had any significant pathology. The mothers were also asked for information about the smoking habit particularly before and during pregnancy. Thirty mothers (46%) were active smokers before and during pregnancy while 35 (54%) declared no history of cigarette smoking. Since the retrospective assessment of the smoking habit of a mother, mainly after the death of his son, is sometimes unavoidable, the negative self-reports were verified by the urinary measuring of cotinine, the main metabolite of nicotine.

2.1. Consent

Parents of all the victims of the study provided written informed consent to autopsy, with the Milan University L. Rossi Research Center institutional review board approval.

2.2. Anatomopathological protocol

The victims were subjected to a complete autopsy, including examination of the placental disk, umbilical cord and membranes in perinatal deaths. In all cases an in-depth histological examination of the autonomic nervous system was made, according to the protocol routinely followed by the "Lino Rossi Research Center for the study and prevention of unexpected perinatal death and the SIDS" of Milan University [23,24].

After fixation in 10% phosphate-buffered formalin, the brains were processed and embedded in paraffin. In particular, transverse serial sections of the midbrain, pons, medulla oblongata and spinal cord (cervico-thoracic tract), where the main structures controlling the vital functions are located, were made at intervals of 60 μm. For each level, six–seven 5 μm sections were obtained, two of which were stained for histological examination using hematoxylin–eosin and Klüver–Barrera stains, two sections for immunohistochemical detection of NeuN and apoptosis, respectively. The remaining sections were saved for further investigations and stained as deemed necessary.

The routine histological evaluation of the brainstem was focused on the locus coeruleus, the parafacial/facial complex, the superior olivary complex, the retrotrapezoid nucleus, the superior olivary nucleus, the parabrachial/Kölliker–Fuse complex in the pons/mesencephalon; on the hypoglossus, the dorsal motor vagal, the tractus solitarius, the ambiguus, the pre-Bötzinger, the inferior olivary and the arcuate nuclei in the medulla oblongata and the intermediolateral nucleus in the spinal cord.

In 35 cases, after the in-depth autoptic examination, the death remained totally unexplained. A diagnosis of "sudden intrauterine unexplained death syndrome/SIUDS" was therefore made for 16 fetuses, who died suddenly after the 17th gestational week before complete expulsion or retraction from the mother, and a diagnosis of "sudden infant death syndrome/SIDS" for 15 infants who died within the first ten months of life. In the remaining 30 cases, 13 stillbirths, and 17 infants, a precise cause of death was formulated at autopsy. These cases were regarded as "controls".

Table 1 summarizes the case profiles in this study, indicating the sex distribution, range of ages, death diagnoses and maternal smoking habit.

2.2.1. Immunohistochemical techniques

2.2.1.1. NeuN immunohistochemistry. Representative sections from paraffin-embedded tissue blocks were stained using commercially supplied mouse monoclonal antibodies against the neuronal nuclear antigen NeuN (Millipore Chemicon International, MAB377). A standard avidin–biotin complex (ABC) technique was used with peroxidase–diaminobenzadine to visualize and develop the antigen–antibody reaction. The antibody dilution at 1:100 was used. Incubating solutions were boiled in boilded in citrate bufferat pH 6.0, in a microwave oven, for 5 min at high power, then 5 min at 50% power, and finally cooled for 20 min. Sections were counterstained lightly with Mayer's hematoxylin.

Evaluation of the NeuN immunohistochemical results. Since in health status the NeuN immunopositivity is diffused in almost the entire brain, for a uniform and representative evaluation of the results we selectively examined at light microscope only the histological sections from the caudal pons given the general presence, above all in the ventral portion, of a wide diffuse population of neurons (the so called "*griseum pontis*").

Only the cells with intense brown immunostaining were considered to be really positive. Moreover, also a weak brown intensity was taken into account.

We quantified the scoring for each case, using a ×40 lens, as follow:

− = no positive cell (*negativity*)
+ = a number of positive cells ≤ 30% per unit area (*moderate positivity*)
−/+ = a number of cells with only weak positivity ≤ 30% per unit area (*weak positivity*)
++ = a number of positive cells > 30% per unit area (*strong positivity*).

The unit area was represented by square millimeteter (mm^2).

2.2.1.2. Apoptosis detection. To detect cells undergoing apoptosis, we applied the TUNEL method and immunohistochemistry for Caspase 3.

TUNEL staining. To detect cells undergoing apoptosis, we used the technique of Terminal-Transferase dUTP Nick End labeling (TUNEL Apoptag plus peroxidase in situ Apoptosis detection kit, S7101, Chemicon). Sections were pretreated with proteinase k (20 μg/ml) for 15 min. Endogenous hydrogen peroxidase activity was quenched

Table 1
Case profiles of the study.

Victims	Age (range)	Sex		Death diagnosis	
		M	F	Explained death Controls (n.30)	Unexplained death (n.35)
Fetuses (n.29)	17–40 gw	12	15	Necrotizing chorioamnionitis (n.7) Congenital heart disease (n.5) Potter's syndrome (n.1) *Smoking mothers (n.3)*	SIUDS (n.16) *Smoking mothers (n.12)*
Infants (n.36)	1–10 m	20	16	Pneumonia (n.6) Congenital heart disease (n.10) Pericarditis (n.1) *Smoking mothers (n.1)*	SIDS (n.19) *Smoking mothers (n.14)*

gw = gestational week; m = month.
SIDS = Sudden Infant Death Syndrome.
SIUDS = Sudden Intrauterine Unexplained Death Syndrome.

in 3% hydrogen peroxide. After a series of rinsing, nucleotides labeled with digoxigenin were enzymatically added to the DNA by terminal deoxy nucleotidyl transferase enzyme (TdT). The incubation was carried out for 60 min the labeled DNA was detected using anti-digoxigenin-peroxidase for 30 min. The chromogen diaminobenzidine tetra hydrochloride (DAB) resulted in a brown reaction product. Incubation without TdT served as negative control.

Caspase 3 immunohistochemistry. Immunohistochemistry was performed with mouse monoclonal IgG antibody (Vector LABS # VP-C308) against a 182 amino acid region of the caspase-3 CPP32 molecule. Deparaffinized/rehydrated sections were boiled in citrate solution for antigen retrieval by microwaving, after blocking endogenous peroxidase with 3% H_2O_2. Incubation with primary antibody (1:40) was overnight. Samples were washed with PBS and processed with avidin–biotin-immunoperoxidase. Counterstaining was with Mayer's hematoxylin.

For all the methods, the slides were examined by two independent and blinded observers comparing the results to evaluate the inter-observer reproducibility. In cases of discordance among the investigators, the slides were reviewed and discussed until a unanimous diagnosis was obtained.

2.3. Statistical analysis

The statistical significance of direct comparisons between the groups of victims was determined using analysis of variance (ANOVA). Statistical calculations were carried out with SPSS statistical software. Statistical significance was set at a value of $p < 0.05$.

3. Results

Table 2 shows the NeuN expression scores observed in victims of perinatal death.

In control cases, from the 27th week of gestation to 10 postnatal months, the major part of the neurons exhibited NeuN immunostaining. In particular, the examination of the *griseum pontis*, the selected region as standard parameter to compare the results, showed in 24 out of 30 control cases strong NeuN-immunoreactivity in almost all the neuronal cell population (Score ++). The staining was present in both nuclei and cytoplasm, extending into the proximal parts of the processes, whereas more distal axons and dendritic ramifications were unlabeled (Fig. 1). These neurons were organized in clusters with irregular shape and size (thereby constituting the "pontine nuclei") separated by bundles of longitudinally and horizontally coursing pontocerebellar fibers (Fig. 2). In the remaining 6 cases the immunopositivity was limited to a neuronal percentage less than 30% (moderate positivity; Score +).

The *griseum pontis* in SIUDS/SIDS cases did not show any changes in the number or morphology of neurons compared with the same area in controls. Nevertheless, the NeuN-labeling was significantly decreased. Precisely, total loss of immunoreactivity (nuclear as well cytoplasmic; Score −) resulted in 63% of SIDS and 69% of SIUDS cases (Fig. 3a). A reduction in staining intensity with a light nuclear signal (weak positivity; Score −/+) was observed in further 21% of SIDS and 6% of SIUDS (Fig. 3b).

In all, 28 of the 35 victims of sudden unexplained death (80%) showed loss or decreased neuronal maturity, while the NeuN was constantly expressed in age-matched controls ($p < 0.01$).

The reduction of NeuN-staining intensity in SIUDS/SIDS cases does not necessarily mean neuronal degeneration and loss of morphological integrity. In fact, the application of the TUNEL-method revealed apoptotic features only in small cells (interneurons and glial cells) scattered in pontine nuclei, whereas positive neurons were rarely or not detected (Fig. 4). On the contrary, Caspase 3 was prevalently expressed in neuronal cells, all showing undamaged nuclear and cellular boundaries (Fig. 5).

In control cases, neurons with typical morphological apoptotic features (cellular shrinkage and condensation of nucleus) were both Caspase 3 and TUNEL positive; neurons with normal appearance only occasionally were diagnosed as died and/or dying cells with the specific immunomethods.

Another important finding of this study was the significant association between decreased NeuN immunostaining and cigarette smoke exposure ($p < 0.01$). In fact, in 25 of the 28 cases of SIUDS/SIDS with NeuN depletion, the mothers belonged to the smoking category.

3.1. Additional results on brainstem

The presented NeuN analyses complemented the brainstem alterations highlighted in this patient series in our previous works. These findings included the hypoplasia/agenesis of the arcuate, the pre-Bötzinger, the inferior olivary, parafacial and serotonergic raphé nuclei, and a wide spectrum of pathological changes of the ependyma (namely desquamation, clusters of ependymal cells in subventricular zone). No correlation was found between NeuN immunonegativity and hypodevelopment of specific brainstem structures.

4. Discussion

The application of the immunohistochemistry using antiNeuN antibody provides the neuropathologists with an easy method to examine the stage of maturation and differentiation of the human CNS. NeuN is in fact a transcriptional factor that is expressed in the nucleus and

Table 2
NeuN immunopositivity score in pontine tegmentum.

Study groups	NeuN immunopositivity Score			
	−	−/+	+	++
SIUDS (n = 16)	11 (69%)	1(6%)	4 (25%)	–
SIDS (n = 19)	12 (63%)	4 (21%)	3 (16%)	–
Fetus controls (n = 13)	–	–	2 (15%)	11(85%)
Infant controls (n = 17)	–	–	4 (24%)	13 (76%)

SIDS = Sudden Infant Death Syndrome; SIUDS = Sudden Intrauterine Unexplained Death.
− = no positive cell (*negativity*)
+ = a number of positive cells ≤ 30% per mm^2 (*moderate positivity*)
−/+ = a number of cells with only weak positivity ≤ 30% per mm^2 (*weak positivity*)
++ = a number of positive cells > 30% per mm^2 (*strong positivity*).

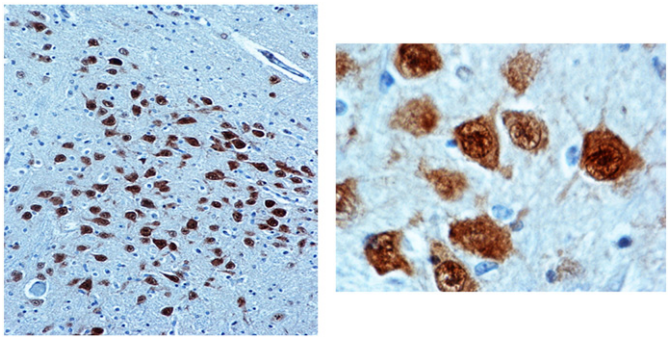

Fig. 1. Transverse section of caudal pons of a 36-week human fetus of the control group. NeuN-immunoreactive neurons are seen, at higher magnification in the right image. The staining is present in both nuclei and cytoplasm, extending into the proximal part of the processes — NeuN immunostaining. Magnification: left image 20× and right image 40×.

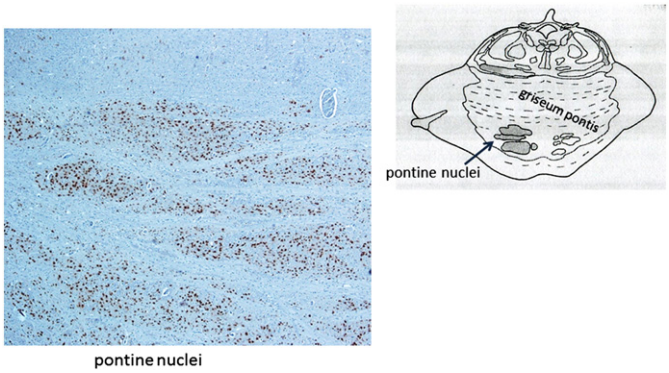

Fig. 2. Immunopositive pontine nuclei in a 3 month-old infant of the control group. On the right schematic representation of a caudal pontine section indicating the localization of the pontine nuclei. Left image: NeuN immunostaining. Magnification 10×.

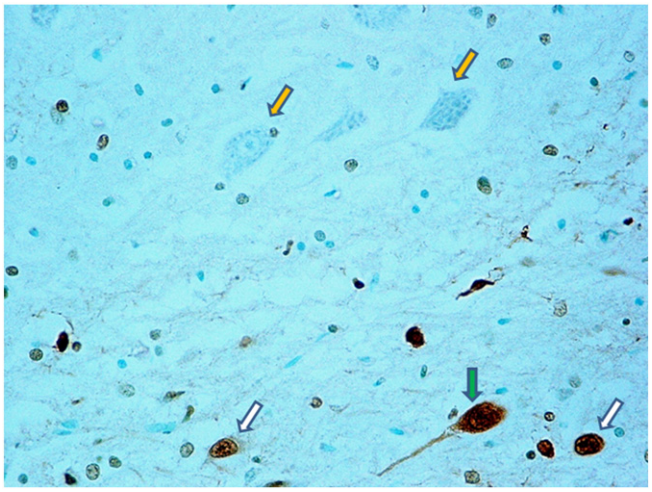

Fig. 4. TUNEL immunostaining of pontine nuclei of a SIDS case (2-month-old). Positivity affects only interneurons (green arrow) and glial cells (white arrows), whereas neurons are TUNEL-negative (yellow arrows) — TUNEL (DNA Nick End Labeling) method. Magnification: 40×.

cytoplasm of neurons in postmitotic stage when start to differentiate into mature cells functionally and morphologically [1,2]. So, immature neuronal cells are negative for NeuN.

Even if NeuN immunopositivity appears diffuse in post-embryonic brain parenchima, this study, performed on a wide set of perinatal deaths, was designed as a detailed survey of NeuN expression in representative pontine coronal sections, given the presence in the ventral side (precisely, in the *griseum pontis*) of a noteworthy number of neurons. We firstly documented strong pattern of expression of this antigen in control subjects, died in perinatal period of known cause; then we reported that normal appearing neurons in the great part of SIUDS/SIDS victims (80%) failed to be marked by the specific antibody or showed weak nuclear NeuN immunoreactivity.

Although the pathophysiology of these results is not fully understood, the different pattern of NeuN expression in sudden perinatal deaths compared to controls is intriguing.

The reduction in immunostainability has been considered as evidence of neuronal death in several experimental studies [25,26]. In particular, Davoli et al. [25], after double labeling with TUNEL and NeuN, showed that the depletion of NeuN immunoreactivity in rat brains after ischemic insults was correlated with an increase of neuronal apoptosis. However, in our study, the NeuN-immunonegative neurons in SIUDS/SIDS victims preserved their cellular integrity with intact nuclear membrane and no sign of disintegration. In addition, TUNEL-immunopositivity only affected interneurons and glial cells, while the great part of neurons did not disclose apoptotic features. Caspase 3 immunopositivity was instead predominantly confined to NeuN negative neurons.

Caspase-3 is one of the primary executioners of apoptosis playing an essential role in the initiation and regulation of the downstream proteolytic events leading to cell death [22,27]. The detection of activated Caspase 3 could therefore be a valuable and specific tool for identifying early apoptotic cells in tissue sections, even before the occurrence of the typical morphological features of apoptosis. It is important to note, however, that apoptosis may occur without Caspase activation and that Caspase-3 may be activated independently from cell death events [28–30].

Hence, loss of NeuN labeling in neurons with healthy appearance does not necessarily indicate an ongoing dying process, but more

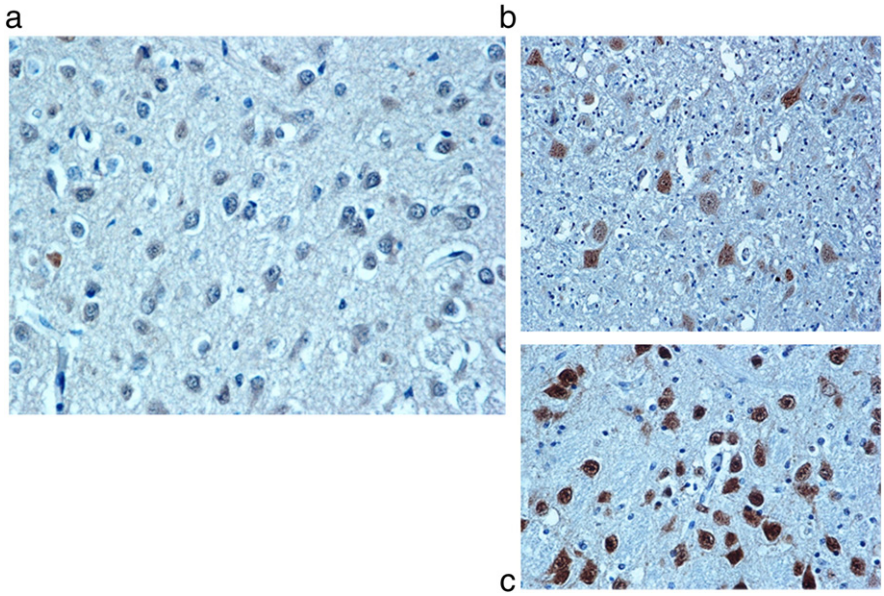

Fig. 3. a) NeuN-immunonegative neurons in pontine nuclei of a SIDS victim dead at 2 months. b) Weak immunopositivity in several neurons belonging to pontine nuclei of a 3-month-old SIDS case. c) NeuN_immunopositivity of a control case (late fetal death — 38 gestational weeks) for comparison — NeuN immunostaining. Magnification: a), b) and c) 20×.

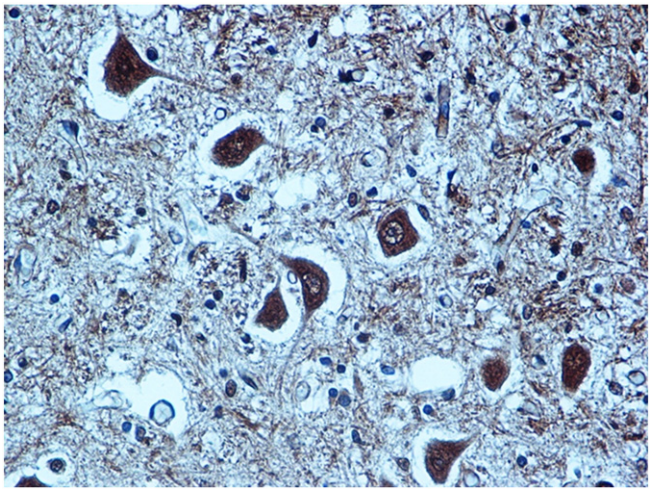

Fig. 5. Activated-caspase 3 immunopositive neurons in a late fetal death (40 gestational weeks) — activated-caspase 3 (AC3) immunohistochemistry. Magnification 40×.

simply a decrease of NeuN protein synthesis or change of its antigenicity. Our supposition is in agreement with the work of Unal-Cevik et al. [31]. These authors demonstrated that the decrease of the NeuN staining in mouse brain after cerebral ischemia does not mean neuronal loss but rather the presence of functional troubles, such as antigen alterations, synaptic dysfunctions and impaired chemoreception, a fundamental mechanism to achieve life-sustaining functions [32,33].

Anyway, the presence of neuronal NeuN-immunonegativity in sudden deaths and the absence of these changes in age-matched controls were accepted as the convincing evidence of a general decreased viability of neurons in these pathologies, probably as a consequence of insulting events. Neuronal NeuN immunoreactivity has been reported in fact to decrease under several pathologic conditions, such as cerebral ischemia, hypoxia and trauma [6–8].

Maternal smoking in pregnancy is a primary determinant of hypoxic/ischemic brain damage particularly in victims of unexplained death [34,35]. Here is one possible explanation: the carbon monoxide, a gaseous combustion product of nicotine, easily crosses the placental barrier by passive diffusion, where it binds to hemoglobin. Consequently, carboxyhemoglobin, that is present in the fetal compartment at concentrations that are generally 15% higher than the maternal levels, inhibits the release of oxygen into fetal tissues, causing hypoxia with consequent delayed maturation of all the organs, especially those most susceptible to hypoxic damage, including the brain [34,35]. Besides, nicotine is one of the few lipid-soluble substances that can go beyond the blood–brain barrier and act directly on the expression of genes modulating the developing brain, i.e. by inducing specific molecular alterations in the DNA, RNA, and antigenic proteins of the nervous cells [36,37].

In agreement with these considerations is the observation in this study of a significant relation between maternal smoking and NeuN deficient expression in sudden unexplained perinatal death. This implies that smoke exposure in pregnancy makes the neurons remarkably vulnerable, easily resulting in an unfavorable physiological outcome.

We have however to underline the possible involvement in this pathogenetic mechanism of more global environmental factors, such as air pollution. In fact many victims included in this study were from Lombardy, a highly polluted Italian region, in which the mean $PM_{2.5}$ and P_{10} levels are recognized to contribute in a substantial way to perinatal mortality. Air pollution may directly affect brain structures through a variety of cellular and molecular pathways, including a decrease of the antigenic expression [38,39].

Anyway this study provide novel approaches to evaluating the causes that can contribute to the sudden death, although further studies are undoubtedly necessary to clarify the role and the functionality of the NeuN.

In conclusion, given the different NeuN expressions here reported in brains of subjects who suddenly died compared to controls, we recommend to include the NeuN immunohistochemistry as a routine method in neuropathologic protocols in order to individuate signs of neuronal suffering and/or immaturity particularly in cases of sudden perinatal death.

Conflict of interest

All authors declare that they have no conflicts of interest, financial or otherwise to declare.

Acknowledgments

This study was supported by the Italian Health Ministry in accordance with Law 31/2006 "*Regulations for Diagnostic Post Mortem Investigation in Victims of Sudden Infant Death Syndrome (SIDS) and Unexpected Fetal Death*" and by the Convention between the *Provincia autonoma di Trento* and the *"Lino Rossi" Research Center of the University of Milan, Italy*.

References

[1] Mullen RJ, Buck CR, Smith AM. NeuN, a neuronal specific nuclear protein in vertebrates. Development 1992;116:201–11.
[2] Sarnat HB, Nochlin D, Born DE. Neuronal nuclear antigen (NeuN): a marker of neuronal maturation in early human fetal nervous system. Brain Dev 1998;20:88–94.
[3] Molliver ME, Kostovic I, van der Loos H. The development of synapses in cerebral cortex of the human fetus. Brain Res 1973;50:403–7.
[4] Weyer A, Schilling K. Development and cell type-specific expression of the neuronal marker NeuN in the murine cerebellum. J Neurosci Res 2003;73:400–9.
[5] Wolf HK, Buslei R, Schmidt-Kastner R, et al. NeuN: a useful neuronal marker for diagnostic histopathology. J Histochem Cytochem 1996;44:1167–71.
[6] Schmidt-Kastner R, Robertson GS, Hakim A. Monoclonal antibody to NeuN as specific marker for neurons in immunohistochemical evaluation of global ischemic damage in rat. J Cereb Blood Flow Metab 1995;15(Suppl. 1):S230.
[7] Igarashi T, Huang TT, Noble LJ. Regional vulnerability after traumatic brain injury: gender differences in mice that over express human copper, zinc superoxide dismutase. Exp Neurol 2001;172:332–41.
[8] Xu GP, Dave KR, Vivero R, Schmidt-Kastner R, Sick TJ, Pérez-Pinzón MA. Improvement in neuronal survival after ischemic preconditioning in hippocampal slice cultures. Brain Res 2002;952:153–8.
[9] Goldwater PN. Sudden infant death syndrome: a critical review of approaches to research. Arch Dis Child 2003;88:1095–100.
[10] Hunt CE. The cardiorespiratory control hypothesis for sudden infant death syndrome. Clin Perinatol 1992;19:757–71.
[11] Krous HF, Beckwith JB, Byard RW, et al. Sudden infant death syndrome and unclassified sudden infant deaths: a definitional and diagnostic approach. Pediatrics 2004;114:234–8.
[12] Kinney HC. Brainstem mechanisms underlying the sudden infant death syndrome: evidence from human pathologic studies.Dev Psychobiol 2009;51:223–33 [Review].
[13] Lavezzi AM, Ottaviani G, Ballabio GM, Rossi L, Matturri L. Preliminary study on the cytoarchitecture of the human parabrachial/Kölliker–Fuse complex with reference to sudden infant death syndrome and sudden intrauterine unexplained death. Pediatr Dev Pathol 2004;72:171–9.
[14] Lavezzi AM, Matturri L. Functional neuroanatomy of the human pre-Bötzinger complex with particular reference to sudden unexplained perinatal and infant death. Neuropathology 2008;28:10–6.
[15] Lavezzi AM, Matturri L. Hypoplasia of the parafacial/facial complex: a very frequent finding in sudden unexplained fetal death. Open Neurosci J 2008;2:1–5.
[16] Lavezzi AM, Alfonsi G, Matturri L. Pathophysiology of the human locus coeruleus complex in fetal–neonatal sudden unexplained death. Neurol Res 2013;35(1):44–53.
[17] Lavezzi AM, Mehboob R, Matturri L. Developmental alterations of the spinal trigeminal nucleus disclosed by substance P immunohistochemistry in fetal and infant sudden unexplained deaths. Neuropathology 2011;31:405–13.
[18] Matturri L, Minoli I, Lavezzi AM, Cappellini A, Ramos S, Rossi L. Hypoplasia of medullary arcuate nucleus in unexpected late fetal death (stillborn infants): a pathologic study. Pediatrics 2002;109:E43.
[19] Matturri L, Lavezzi AM. Pathology of the central autonomic nervous system in stillbirth. Open Ped Med J 2007;1:1–9.
[20] Ansari B, Coates PJ, Greenstein BD, Hall PA. In situ end-labelling detects DNA strand breaks in apoptosis and other physiological and pathological states. J Pathol 1993;170:1–8.
[21] Huppertz B, Frank HG, Kaufmann P. The apoptosis cascade—morphological and immunohistochemical methods for its visualization. Anat Embryol (Berlin) 1999;200:1–18.
[22] Thornberry NA. Caspases: a decade of death research. Cell Death Differ 1999;6:1023–7.

[23] Matturri L, Ottaviani G, Lavezzi AM. Techniques and criteria in pathologic and forensic-medical diagnostics of sudden unexpected infant and perinatal death. Am J Clin Pathol 2005;124:259–68.
[24] Matturri L, Ottaviani G, Lavezzi AM. Guidelines for neuropathologic diagnostics of perinatal unexpected loss and sudden infant death syndrome (SIDS). A technical protocol. Virchows Arch 2008;452:19–25.
[25] Davoli MA, Fortunis J, Tam J, Xanthoudakis S, Nicholdon D, Robertson GS, et al. Immunohistochemical and biochemical assessment of caspase-3 activation and DNA fragmentation following transient focal ischemia in the rat. Neuroscience 2002;115: 125–36.
[26] Sugawara T, Lewen A, Noshita N, Gasche Y, Chan HP. Effects of global ischemia duration on neuronal, astroglial, oligodendroglial and microglial reactions in the vulnerable hippocampal CA1 subregion in rats. J Neurotrauma 2002;19: 85–98.
[27] D'Amelio M, Sheng M, Cecconi F. Caspase 3 in the central nervous system: beyond apoptosis. Trends Neurosci 2012;35:700–9.
[28] Abraham MC, Shaham S. Death without caspases, caspases withouth death. Trends Cell Biol 2004;14:184–93.
[29] Newton K, Strasser A. Caspases signal not only apoptosis but also antigen-induced activation in cells of the immune system. Genes Dev 2003;17:819–25.
[30] Hyman BT. Caspase activation without apoptosis: insight into Aβ initiation of neurodegeneration. Nat Neurosci 2011;14:5–6.
[31] Unal-Cevik I, Kilinç M, Gürsoy-Ozdemir Y, Gurer G, Dalkara T. Loss of NeuN immunoreactivity after cerebral ischemia does not indicate neuronal cell loss: a cautionary note. Brain Res 2004;1015:169–74.
[32] Nattie EE. Central chemoreceptors, pH and respiratory control. In: Kaila K, Ransom, BR, editors. pH and Brain Function. New York: Wiley-Liss; 1998. p. 536–60.
[33] Feldman JL, Mitchell S, Nattie EE. Breathing: rhythmicity, plasticity, chemosensitivity. Annu Rev Neurosci 2003;26:239–66.
[34] Duncan JR, Garland M, Myers MM, Fifer WP, Yang M, Kinney HC, et al. Prenatal nicotine-exposure alters fetal autonomic activity and medullary neurotransmitter receptors: implications for sudden infant death syndrome. J Appl Physiol 2009;107: 1579–90.
[35] Lavezzi AM, Ottaviani G, Matturri L. Adverse effects of prenatal tobacco smoke exposure on biological parameters of the developing brainstem. Neurobiol Dis 2005;20:601–7.
[36] Lichtensteiger W, Ribary U, Schiumpf M, Odermatt B, Widemer HR. Prenatal adverse effects of nicotine on the developing brain. Prog Brain Res 1988;73:137–57.
[37] Gressens P, Laudenbach V, Marret S. Mechanisms of action of tobacco smoke on the developing brain. J Gynecol Obstet Biol Reprod (Paris) 2003;32(1 Suppl.):30–2.
[38] Calderón-Garcidueñas L, Azzarelli B, Acuna H, Garcia R, Gambling TM, Osnaya N, et al. Air pollution and brain damage. Toxicol Pathol 2002;30:373–89.
[39] Genc S, Zadeoglurary Z, Fuss SH, Genc K. The adverse effects of air pollution on the nervous system. J Toxicol 2012;2012:23 [ID 782462].