

Involvement of somatostatin in breathing control before and after birth, and in perinatal and infant sudden unexplained death

Anna Maria Lavezzi, Giulia Ottaviani, Luigi Maturri

Institute of Pathology, University of Milan, Italy

The distribution of the somatostatin was studied by immunohistochemistry on serial sections of the 56 brain stems from subjects aged from 30 gestational weeks to 12 postnatal months, dying of both known and unknown causes. The unexplained deaths included 13 sudden intrauterine deaths, 4 sudden neonatal deaths and 24 sudden infant deaths. We observed intense somatostatin positivity in the cell bodies and fibres of many brainstem nuclei prevalently involved in the respiratory activity (parabrachial/Kölliker-Fuse complex, locus coeruleus, hypoglossus nucleus, dorsal vagus motor nucleus, tractus solitarius nucleus, ambiguous nucleus, and reticular formation) in stillbirths. Only in 8 fetuses with unexplained death the hypoglossus nucleus was somatostatin-negative. In the postnatal deaths, the immunopositivity was prevalently limited to the ventrolateral and ventral subnuclei of the tractus solitarius nucleus. In 13 sudden infant death victims and in one case of death due to pneumonia, somatostatin-positivity was also present in the hypoglossus nucleus. We concluded that: 1) the somatostatin is an important foetal breathing-inhibitor, but it becomes important for the physiological control of respiration immediately after delivery; 2) functional alterations of the hypoglossal nucleus can occur in both sudden perinatal and infant deaths and contribute to the induction of both fatal breathing movements in fetuses and abnormal ventilatory control in infants leading to irreversible apneic phenomena.

key words: somatostatin, SIUD, SNUD, SIDS, breathing

INTRODUCTION

Somatostatin (SS) is a neuropeptide with a wide distribution in the central nervous system (CNS), which controls various physiological processes, including cardiovascular, digestive and respiratory activity [9, 12, 28, 37], through interaction with specific receptors [31, 32, 35].

Experimental studies have shown that SS is particularly expressed in the nuclei of the brainstem in-

involved in ventilatory regulation, such as the tractus solitarius nucleus, dorsal vagus motor nucleus, ambiguous nucleus, parabrachialis nuclei [4, 7, 30, 39].

Several authors have demonstrated that local injections of SS into the brainstem of rats and cats induce changes in respiratory rhythm and can also cause ventilatory depression and irreversible apnea [5, 13, 14, 18].

In man, it was observed that intravenous administration of SS could induce inhibition of the ventilatory response to hypoxia [11, 27]. However, only few controversial studies have described the distribution of SS and of its receptors in the human brain [2, 3, 6, 8, 33].

Address for correspondence: Prof. Anna Maria Lavezzi, MD
 Institute of Pathology, University of Milan
 Via della Commenda, 19, 20122 Milan, Italy
 tel./fax: +39-02-5419538
 e-mail: anna.lavezzi@unimi.it
 web site: <http://users.unimi.it/~patol/pathol.html>

To obtain basic information about the expression of SS in the human CNS and, in particular, to evaluate the possible involvement of this neurotransmitter in unexplained perinatal and in sudden infant death syndrome, which we have frequently ascribed to morphological alterations of respiratory centres [1, 22–25], we performed an immunohistochemical study on serial sections of the brainstems of subjects aged from 30 gestational weeks to 12 postnatal months, who died of known and unknown causes.

MATERIAL AND METHODS

We examined 56 brainstems obtained at autopsy from 18 stillbirths and 38 infants aged from 30 gestational weeks to 12 postnatal months. Six cases were neonatal deaths that occurred in the first week of life (Table 1).

In 13 stillborns, 4 newborns and 24 infants death occurred suddenly and unexpectedly and remained unexplained after a thorough case investigation and a complete autopsy, including examination of the placental disk, umbilical cord and membranes in foetuses.

A diagnosis of Sudden Intrauterine Unexplained Death (SIUD) was established for the 13 stillborns. The 4 newborns died of Sudden Neonatal Unexplained Death (SNUD). The Sudden Infant Death Syndrome (SIDS) was diagnosed in the 24 infants, who all died unexpectedly after the first month of life. 70% of the SIDS cases were 3 to 6 months old.

In the other cases, the cause of death was established at autopsy, and included atypical location of the umbilical cord (2 foetuses), congenital heart diseases (2 foetuses; 2 newborns; 1 infant), pneumonia (1 foetus; 2 infants), acute infections (5 infants).

Table 1. Sources of the brainstems

| Victim groups | Diagnosis |
|------------------|--------------------------------------|
| Fetuses (n = 18) | SIUD (n = 13) |
| | Malpositioned umbilical cord (n = 2) |
| | Congenital heart disease (n = 2) |
| | Pneumonia (n = 1) |
| Newborns (n = 6) | SNUD (n = 4) |
| | Congenital heart disease (n = 2) |
| Infants (n = 32) | SIDS (n = 24) |
| | Congenital heart disease (n = 1) |
| | Pneumonia (n = 2) |
| | Acute infections (n = 5) |

SIUD – Sudden Intrauterine Unexplained Death, SNUD – Sudden Neonatal Unexplained Death, SIDS – Sudden Infant Death Syndrome

All brainstems were fixed in 10% phosphate-buffered formalin, processed and embedded in paraffin, according to the protocol routinely followed by our Institute [26] and available on the web site: http://users.unimi.it/~patol/sids/_e.html. Briefly, transverse serial sections were made through the entire extension: the block was cut at intervals of 30 μ m. For each level, twelve 5 μ m sections were obtained, three of which were routinely stained for histological examination using alternately hematoxylin-eosin, Bielschowsky and Klüver-Barrera stains, two for the SS immunohistochemical study and the other 7 were saved and stained as deemed necessary for further investigations. The number of levels and consequently of serial sections throughout the entire brainstem varied in relation to the age of the analysed subjects. In foetuses, from the 30th week of gestation, the average number of sections was 360 (corresponding to 30 groups of 12 serial sections), while in term foetuses and/or in newborns it was 600 (30 groups). In infants of 3–4 months or over 6 months an average of 900 and 1,400 sections were obtained from 75 and 120 levels, respectively.

The principal nuclei in the histological serial sections were analysed, namely the parabrachial/Kölliker-Fuse complex (PB/KF), the locus coeruleus (LC), the hypoglossus nucleus (HypogIN), the dorsal vagus motor nucleus (DvmN), the tractus solitarius nucleus (TsN), the ambiguous nucleus (AmbN), the arcuate nucleus (ArcN), the ventrolateral respiratory reticular formation (RF) and the inferior olivary nucleus (OliN). Plates in the Olszewski and Baxter atlas [29] were used as references.

SS immunohistochemistry

Lyophilised rabbit serum diluted in PBS (Novocastlab- Newcastle, UK) was used in this study. This antiserum recognised the N-terminal part of SS-28, composed of 28 amino acids.

SS immunoreactivity was visualised by the peroxidase-antiperoxidase (PAP) method. In order to neutralise endogenous peroxidase, sections were pretreated with a solution of 0.3% hydrogen peroxide for 20 minutes. After rinsing in buffer, sections were exposed for 48 hours to the specific primary antiserum diluted 1:150 at 25 °C. After 10 min in the buffer, the site of antigen-antibody reaction was revealed with antirabbit immunoglobuline followed by PAP complex. The unlabeled antiserum was placed on the sections (1:200 dilution) for 2 h at room temperature. The sections were then exposed to PAP complex for 2 h at dilution 1:200. The sites of peroxidase activity were visualised with 0.3% hydrogen peroxide in buffer con-

taining 0.04% diaminobenzidine tetrahydrochloride and 0.5 g nickel ammonium sulfate. Slides were rinsed, dehydrated, mounted and examined by light microscopy.

Statistical analysis

The association of the SS positivity in the different brainstem nuclei and victim groups was evaluated by Cox regression analysis. The statistical value of the correlation was established at the $p < 0.05$ level using one-way analysis of variance followed by t-test or Student's t-test.

RESULTS

Histological examination of serial sections of the 56 brainstems often showed a normal morphology of all the principal nuclei throughout their extension. Structural congenital abnormalities of the arcuate nucleus were observed in 15 of the sudden death victims (5 SIUD, 1 SNUD and 9 SIDS) (37%) and in none of the subjects that died of other causes (Table 2).

Different degrees of the arcuate nucleus developmental defect were observed: bilateral hypoplasia in 4 cases (n. 1 SIUD and 3 SIDS), monolateral hypoplasia in 1 case (SIDS), partial hypoplasia in 5 cases (3 SIUD, and 2 SIDS), neuronal depletion and/or delayed neuronal maturation in 3 cases (SIDS) and agenesis in 2 cases (1 SIUD, 1 SNUD).

The hypoplasia of the RF was also present together with ArcN hypodevelopment in 4 SIUD cases.

The immunohistochemical study showed prevalent SS expression in the nuclei of the brainstem involved in respiratory activity but a variable distribution (Table 2). In particular, in stillbirths, an intense positivity was constantly seen in the cell bodies and fibres of the PB/KF and LC in the pons and in the TsN, DvN, AmN and RF in the medulla oblongata. In 10 fetuses (5 SIUD with hypoplasia of the ArcN and 5 deaths of an identified cause), positivity of the neurons of the HypogIN was also observed. In further 8 cases, all classified as SIUD, this nucleus gave a negative result for SS. In these 8 victims, the ArcN showed a normal morphology.

In the positive nuclei, the presence of SS was relatively constant along their caudo-rostral axis except in the DvN, where the more caudal sections gave negative results.

In the postnatal deaths, an abrupt reduction of SS-positivity was evident. In fact, even in the first days of life, we observed a moderate number of positive cell bodies limited to the ventrolateral and ventral subnuclei of the NTS and sometimes to the DvN and LC. In 13 SIDS cases, all with a normal structure of the ArcN, and in one case of death due to pneumonia, concomitant with the positivity in such nuclei, a large group of intensely positive motoneurons was also present in the HypogIN (Fig. 1).

Table 2. Distribution of SS and arcuate nucleus hypoplasia in the cases studied

| Victim groups | | SS positivity | | | | | | | Arc N hypoplasia | |
|---------------------|-------------------------|---------------|-----|-----|-----|-----|----|---------|------------------|----------|
| | | PB/KF | LC | TsN | DvN | AmN | RF | HypogIN | N° cases | N° cases |
| Fetuses (n = 18) | SIUD (n = 13) | + | + | + | + | + | + | - | 8 | - |
| | | + | + | + | + | + | + | + | 5 | 5 |
| | Other causes (n = 5) | + | + | + | + | + | + | + | 5 | - |
| Newborns (n = 6) | SNUD (n = 4) | - | (+) | +* | (+) | - | - | - | 4 | 1 |
| | Other causes (n = 2) | - | - | +* | (+) | - | - | - | 2 | - |
| Infants (n = 32) | SIDS (n = 24) | - | - | +* | (+) | - | - | - | 2 | - |
| | | - | (+) | +* | (+) | - | - | + | 13 | - |
| | | - | (+) | +* | (+) | - | - | - | 9 | 9 |
| | Other causes (n = 8) | - | - | +* | + | - | - | + | 1 | - |
| | | - | (+) | +* | (*) | - | - | - | 7 | - |

SIUD – Sudden Intrauterine Unexplained Death, SNUD – Sudden Neonatal Unexplained Death, SIDS – Sudden Infant Death Syndrome, PB/KF – parabrachial/Kölliker-Fuse complex; LC – locus coeruleus, TsN – tractus solitarius nucleus, DvM – dorsal vagus motor nucleus, AmbN – ambiguus nucleus, RF – ventrolateral reticular formation, HypogIN – hypoglossus nucleus, ArcN – arcuate nucleus.

+* = SS-positivity limited to neurons of the ventral and ventrolateral subnuclei of the TsN.

(+) = SS-positivity only in some cases.

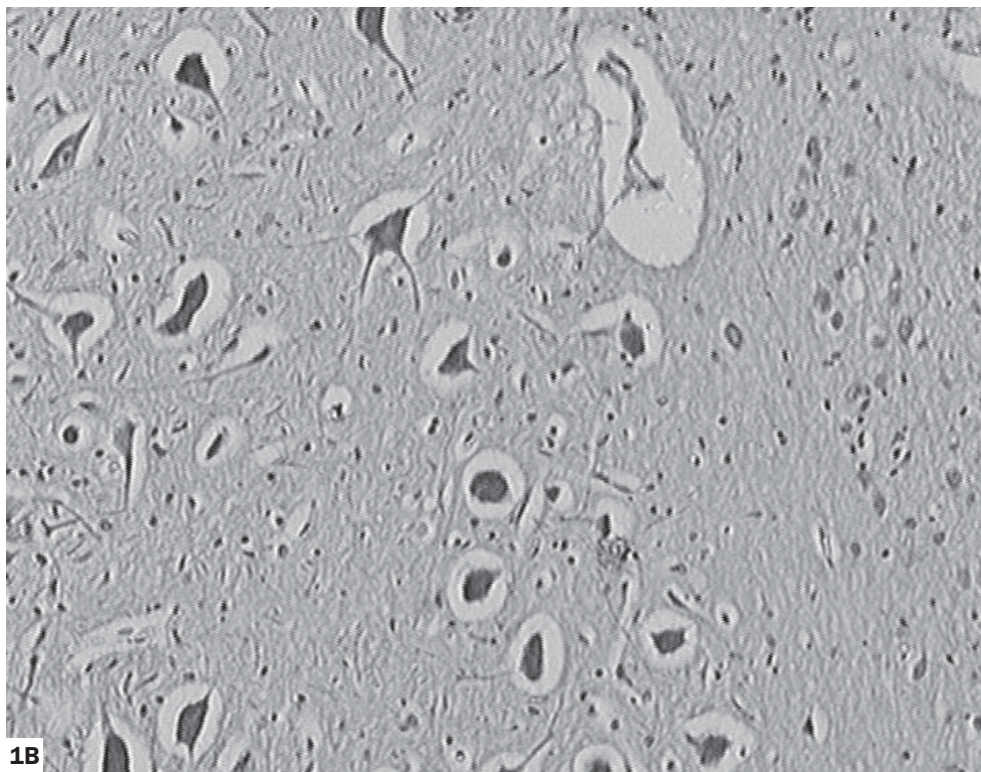
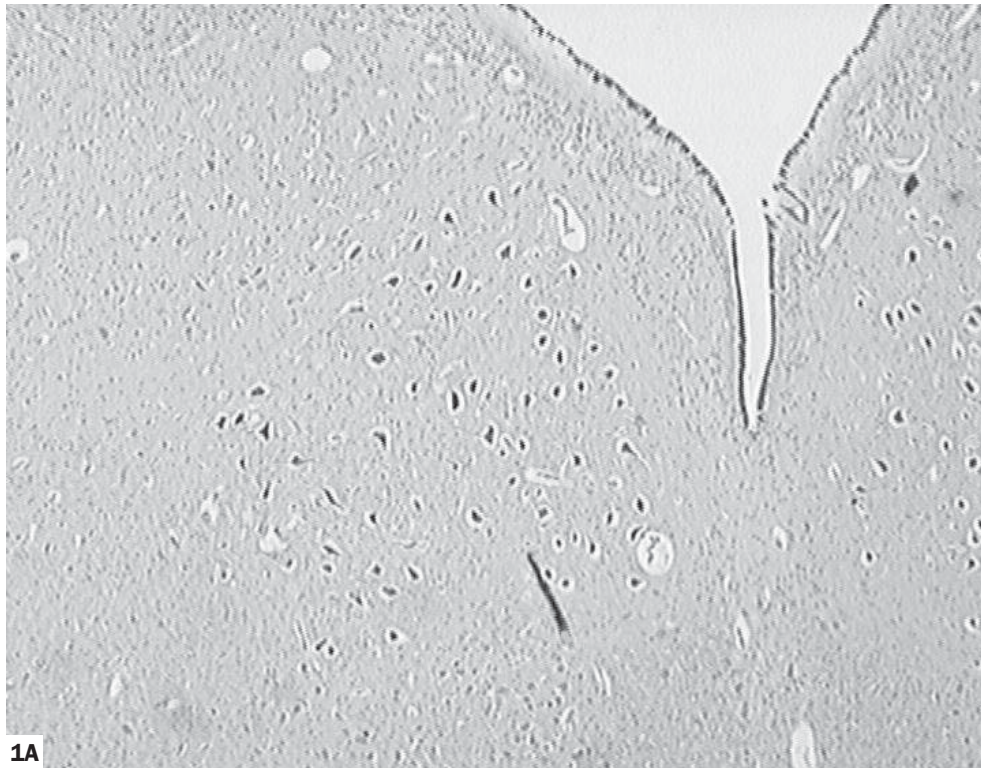


Figure 1. Somatostatin-immunoreactive neurons of the hypoglossus nucleus in a victim of sudden infant death syndrome (male, 3 months).
Magnification: **1A** = $\times 2.5$; **1B** = $\times 10$.

Thus, we found that an altered behaviour of SS in the HypogI/N is significantly related to sudden death ($p < 0.05$). In fact, the observation of a SS-negative HypogI/N is more frequent in SIUD than in foetal deaths of known causes. On the contrary, the frequency of SS-positivity of the HypogI/N is higher in SIDS than in infants dead of other causes.

DISCUSSION

The results obtained in this study give rise to various considerations.

During foetal development, SS-containing neurons are diffusely distributed in many nuclei of the brainstem, showing a particular concentration in the nuclei involved in respiratory activity (TsN, DvN, AmN, RF, HypogI/N, ArcN, PB-KF, LC). This positivity is found in both cell bodies and fibres.

After birth, SS positivity immediately decreases. Its presence is constantly restricted to the perikarya of a smaller number of brainstem nuclei (DvN, LC and, above all, the ventrolateral and lateral subnuclei of the TsN). This pattern of positivity is stable as early as from the first days of life and is maintained up to 12 months.

Similarly, in studies of few cases, Carpentier et al. [2, 3] and Chigr et al. [6] showed that SS-receptors are expressed in many regions of the human brainstem during development in the foetus, particularly in the LC, DvN and TsN, and disappear during infancy and adulthood.

Therefore, we can assume that the high presence of the SS in respiratory centres of the foetal brainstems is strongly involved in the inhibition of intrauterine breathing.

Additionally, the persistence of positive cell bodies in nuclei involved in the regulation of respiration, particularly, in two subnuclei of the TsN (ventral and ventrolateral) after birth, suggests another important role for SS in the modulation of the ventilatory rhythm.

In fact, the ventrolateral and ventral regions of the TsN are known to contain dense concentrations of respiratory neurons. Electrophysiological studies [10, 17, 18] have shown the existence of two populations of neurons in these subnuclei of the TsN (R-alpha and R-beta), which are considered to be excitatory and inhibitory respiratory neurons, respectively.

The involvement of SS in the control of ventilatory activity is also shown by the observation, in cases with a positive DvN, that immunoreactive neurons are prevalently located in the rostral-intermediate extent of this nucleus. In the caudal sections, SS-immunostaining is constantly negative.

These data are in agreement with several experimental studies showing that the DvN contains different neurochemical subpopulations with distinct physiological roles. It is well established that the caudal region of this nucleus is involved in vagal reflexes controlling gastric motility. Instead, the motor neurons with respiratory-related activity are located in the rostral-intermediate levels [21, 36].

The SS-positivity observed in this study, in some cases, relatively to LC, suggests that even this nucleus may participate in the ventilatory activity. Besides, several authors have demonstrated in experimental studies that the noradrenergic neurons of the LC play a critical role in the regulation of the sleep cycle oscillations and of the wakefulness [15, 16, 19, 20].

Therefore, our results show a dual function of SS in the human brainstem: 1) inhibition of foetal breathing and 2) control of the respiratory rhythm after delivery.

Another interesting result of this study is the different expression of SS in the HypogI/N in cases of unexplained death compared to cases with an explained cause of death. In fact, we observed negativity for SS in this nucleus, among the foetal deaths, only in 8 of the 13 SIUD and in no stillbirths who died of known causes. On the contrary, among the infant deaths, the HypogI/N was positive for the SS in 13 of the 24 SIDS cases and only in 1 subject who died of a known cause.

Although the HypogI/N is not included among the classically defined respiratory centres, its motor neurons, which innervate intrinsic and extrinsic muscles of the tongue, are known to produce peaks of activity that coincide with specific phases of respiration after birth [34, 38]. In fact, in the HypogI/N different populations of motoneurons have been identified to act during inspiration, expiration and transitional phases [38]. In particular, the motoneurons that control the tonus of the extrinsic tongue muscles are important in maintaining a patent airway, especially during inspiration.

The different functional behaviour of the HypogI/N as regards SS could reflect a delayed maturation of this nucleus in both prenatal and postnatal sudden deaths.

Therefore, it is possible that abnormalities in the distribution of SS in the HypogI/N before and after birth may contribute to the induction of both fatal breathing movements in fetuses and abnormal ventilatory control in infants leading to irreversible apneic phenomena.

CONCLUSIONS

In this study we postulate that:

- 1) The SS neurotransmitter in the human CNS is an important foetal breathing-inhibitor, but it becomes important to the physiological control of respiration immediately after delivery.

2) Functional alterations of the HypogIIN, attributable to wrong distribution of SS, can occur in both sudden perinatal and infant deaths, without any evidence of structural alteration of the brainstem, including ArcN hypoplasia, which is the histological finding most frequently observed in such cases. Thus, the present immunohistochemical study suggests a plausible explanation in a group of SIUD, SNUD and SIDS that remained unexplained after a thorough case investigation, including a complete autopsy with in-depth histological examination of cardiorespiratory innervation, according to the protocol routinely followed in our Institute.

ACKNOWLEDGEMENTS

Supported by the Region of Lombardy (Project N. 49210-24.3.00. "Program for research on intervention and reduction of the risk of sudden infant death syndrome- SIDS – and unexpected fetal death"). The authors thank Mrs. Lorella Terni for her precious technical assistance. Appreciation is extended to Doctor Mary Victoria Candace Pragnell for English language assistance.

REFERENCES

- Biondo B, Lavezzi AM, Tosi D, Turconi P, Matturri L (2003) Delayed neuronal maturation of medullary arcuate nucleus in SIDS (Sudden Infant Death Syndrome). *Acta Neuropathol*, 106: 545–555.
- Carpentier V, Vaudry H, Laquerrière A, Tayot J, Leroux P (1996) Distribution of somatostatin receptors in the adult human brainstem. *Brain Research* 734: 135–148.
- Carpentier V, Vaudry H, Mallet E, Laquerrière A, Tayot J, Leroux P (1996) Anatomical distribution of somatostatin receptors in the brainstem of the human fetus. *Neuroscience*, 73: 865–879.
- Chen Z, Engberg G, Hedner T, Hedner J (1991) Antagonistic effects of somatostatin and substance P on respiratory regulation in the rat ventrolateral medulla oblongata. *Brain Res*, 556: 13–21.
- Chen Z, Hedner T, Hedner J (1990) Local application of somatostatin in the ventrolateral brain medulla induces apnea in the rat. *J Appl Physiol*, 69: 2233–2238.
- Chigr F, Najimi M, Leduque P, Charnay Y, Jordan D, Chayville JA, Tohyama M, Kopp N (1989) Anatomical distribution of somatostatin immunoreactivity in the infant brainstem. *Neuroscience*, 29: 615–628.
- Cohen MT (1979) Neurogenesis of respiratory rhythm in the mammal. *Physiol Rev*, 59: 1105–1173.
- Cooper PE, Fernstrom MH, Rostad OP, Leeman SE, Martin JB (1981) The regional distribution of somatostatin, substance P and neurotensin in human brain. *Brain Research*, 218: 219–232.
- Epelbaum J (1986) Somatostatin in the central nervous system: physiology and pathological modifications. *Progr Neurobiol*, 27: 63–100.
- Euler C von, Hayward JN, Marttila I, Wyman RJ (1973) Respiratory neurons of the ventrolateral nucleus of the solitary tract of cat: vagal input, spinal connections and morphological identification. *Brain Research*, 61: 1–22.
- Filuk RB, Berezanski DJ, Anthonisen NR (1988) Depression of hypoxic ventilatory response in humans by somatostatin. *J Appl Physiol*, 65: 1050–1054.
- Finley JCW, Maderdrut JL, Roger LJ, Petrusz P (1981) The immunocytochemical localization of somatostatin-containing neurons in the rat central nervous system. *Neuroscience*, 6: 2173–2192.
- Fuxe K, Agnati LF, Harfstrand A, Mutt V, Andersson K, Horkfelt T, Vale W, Brown M, Rivier J (1982) Cardiovascular and respiratory actions of somatostatin peptides following intracisternal injections into the α -chloralose anaesthetized rat. *Neurosci Lett Suppl*, 10: 189.
- Harfstrand A, Kalia M, Fuxe K, Kaijser L, Agnati L (1984) Somatostatin induced apnoea: interaction with hypoxia and hypercapnea in the rat. *Neurosci Lett*, 50: 37–42.
- Hobson JA, McCarley RW, Wyzinski PW (1975) Sleep cycle oscillation: reciprocal discharge by two brainstem neuronal groups. *Science*, 189: 55–58.
- Jones BE (1991) The role of noradrenergic locus coeruleus neurons and neighboring cholinergic neurons of the pontomesencephalic tegmentum in sleep-wake states. *Prog Brain Res*, 88: 533–543.
- Kalia M (1980) Anatomical organization of central respiratory neurons. *Ann Rev Physiol*, 43: 105–120.
- Kalia M, Fuxe K, Agnati LF, Hokfelt T, Harfstrand A (1984) Somatostatin produces apnoea and is localized in medullary respiratory nucleus: a possible role in apnoic syndromes. *Brain Research*, 236: 339–344.
- Kayama Y, Koyama Y (1998) Brainstem neural mechanisms of sleep and wakefulness. *Eur Urol*, 33 (suppl, 3): 12–15.
- Kayama Y, Koyama Y (2003) Control of sleep and wakefulness by brainstem monoaminergic and cholinergic neurons. *Acta Neurochir Suppl*, 87: 3–6.
- Manier M, Mouchet P, Feuerstein C (1987) Immunohistochemical evidence for the coexistence of cholinergic and catecholaminergic phenotypes in neurons of the vagal motor nucleus in the adult rat. *Neurosci Lett*, 80: 141–146.
- Matturri L, Biondo B, Mercurio P, Rossi L (2000) Severe hypoplasia of medullary arcuate nucleus: quantitative analysis in sudden infant death syndrome. *Acta Neuropathol*, 99: 371–375.
- Matturri L, Biondo B, Suárez-Mier MP, Rossi L (2002) Brain stem lesions in the sudden infant death syndrome: variability in the hypoplasia of the arcuate nucleus. *Acta Neuropathol*, 104: 12–20.
- Matturri L, Minoli I, Lavezzi A.M, Cappellini A, Ramos S, Rossi L (2002) Hypoplasia of medullary arcuate nucleus in unexpected late fetal death (stillborn infants): a pathologic study. *Pediatrics*, 109: E43.
- Matturri L, Lavezzi AM, Cappellini A, Ottaviani G, Minoli I, Rubino B, Rossi L (2003) Association between pulmonary hypoplasia and hypoplasia of arcuate nucleus in stillbirth. *J Perinatol*, 23: 328–333.
- Matturri L, Ottaviani G, Alfonsi G, Crippa M, Rossi L, Lavezzi AM (2004) Study of the brainstem, particularly the arcuate nucleus, in Sudden Infant Death Syndrome (SIDS) and Sudden Intrauterine Unexplained Death (SIUD). *Am J Forensic Med Pathol*, 25: 44–48.

27. Maxwell DL, Chahal P, Nolop KB, Hughes JMB (1986) Somatostatin inhibits the ventilatory response to hypoxia in humans. *J Appl Physiol*, 60: 997–1102.
28. Olpe HR, Balcar VJ, Bittiger H, Rink H, Sicher P (1981), Central actions of somatostatin. *Eur J Pharmacol*, 63: 127–133.
29. Olszewski J., Baxter D (1982) *Cytoarchitecture of the human brain stem*. Karger, Basel.
30. Oomura Y, Mizuno Y (1986) Effect of somatostatin on the vagal motor neuron in the rat. *Brain Res Bull*, 17: 397–401.
31. Raynor K, Reisine T (1993) Somatostatin receptors. *CRC Crit Rev Neurobiol*, 16: 273–289.
32. Reisine T, Bell GI (1995) Molecular properties of somatostatin receptors. *Neuroscience*, 67: 777–790.
33. Reuby JC, Cortes R, Maurer R, Probst A, Palacios JM (1986) Distribution of somatostatin receptors in the human brain: an autoradiographic study. *Neuroscience*, 18: 329–346.
34. Roda F, Gestreau C, Bianchi AL (2002) Discharge patterns of hypoglossal motoneurons during fictive breathing, coughing and swallowing. *J Neurophysiol*, 87: 1703–1711.
35. Schindler M, Harrington KA, Humphrey PP, Emson PC (1995) Cellular localization and co-expression of somatostatin receptor messenger RNAs in the human brain. *Mol Brain Res*, 34: 321–326.
36. Tayo EK, Williams RG (1990) Catecholaminergic parasympathetic efferents within the dorsal motor nucleus of the vagus in the rat: a quantitative analysis. *Neurosci. Lett*, 90: 1–5.
37. Vécsei L, Viderlöv E (1990) Preclinical and clinical studies with somatostatin related to the central nervous system. *Prog Neuropsychopharmacol Biol Psychiat*, 14: 473–502.
38. Withington-Wray DJ, Mifflin SW, Spyer KM (1988) Intracellular analysis of respiratory-modulated hypoglossal motoneurons in the cat. *Neuroscience*, 25: 1041–1051.
39. Yamamoto Y, Runold M, Probhakar M, Pantaleo T, Lagercrantz H (1988) Somatostatin in the control of respiration. *Acta Physiol Scand*, 134: 529–533.